

Product datasheet for **TA327674**

EPCAM Mouse Monoclonal Antibody [Clone ID: Ber-EP4]

Product data:

Product Type:	Primary Antibodies
Clone Name:	Ber-EP4
Applications:	IHC
Recommended Dilution:	IHC: 1:50 - 1:200
Reactivity:	Human
Host:	Mouse
Isotype:	IgG1, kappa
Clonality:	Monoclonal
Formulation:	This antibody is supplied as cell culture supernatant diluted in tris buffered saline, pH 7.3-7.7, with 1% BSA and <0.1% sodium azide.
Conjugation:	Unconjugated
Storage:	Store at -20°C as received.
Stability:	Stable for 12 months from date of receipt.
Gene Name:	epithelial cell adhesion molecule
Database Link:	NP_002345 Entrez Gene 4072 Human P16422
Synonyms:	4; DIAR5; EGP-2; EGP40; EGP314; ESA; HNPCC8; KS1; KSA; M4S1; MIC18; MK-1; TACSTD1; TROP1

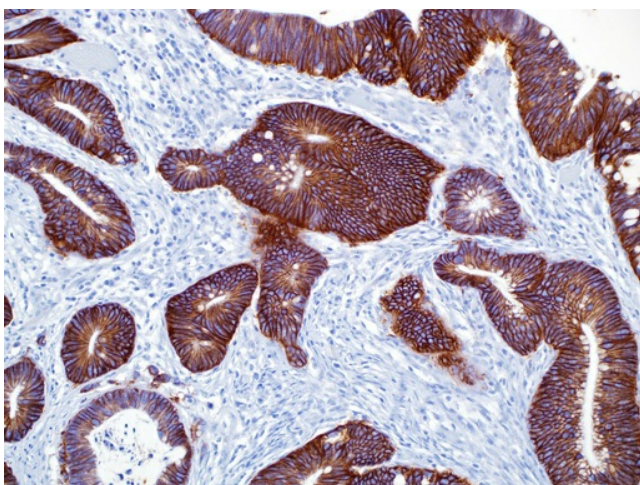


[View online »](#)

Note: Ep-CAM consists of two glycoproteins, 34 and 39 kDa, sometimes designated as epithelial antigen, epithelial specific antigen, or epithelial glycoprotein. In paraffin sections, the protein is detected with mouse anti-human antibodies like anti-Ber-EP4 and anti-MOC-31. The glycoproteins are located on the cell membrane surface and in the cytoplasm of virtually all epithelial cells with the exception of most squamous epithelia, hepatocytes, renal proximal tubular cells, gastric parietal cells, and myoepithelial cells. In liver lesions like hepatitis and cirrhosis, the hepatocytes frequently become anti-Ep-CAM positive. Normal mesothelial cells are anti-Ep-CAM negative, but may express focal reaction when undergoing reactive changes. Ep-CAM is found in the large majority of adenocarcinomas of most sites (50%-100% in various studies) as well as in neuroendocrine tumors, including small cell carcinoma. Renal cell carcinoma and hepatocellular carcinoma stain with anti-Ber-EP4 in about 30% of cases. Basal cell and basosquamous carcinoma are anti-Ber-EP4 positive in almost all cases. Malignant mesothelioma (epithelioid and biphasic) is anti-Ber-EP4 positive in 4%-26% of the cases. The staining is usually focal, but may occasionally be widespread. Synovial sarcoma (epithelioid and biphasic) and desmoplastic small round cell tumor stain with anti-Ber-EP4 in most cases. Seminoma, embryonal carcinoma, yolk sac tumor, and choriocarcinoma reveal anti-Ber-EP4 positivity in a minor proportion of cases. The lack of reactivity in the majority of malignant mesotheliomas can, in an appropriate panel, be utilized to discriminate between this tumor and adenocarcinoma.

Protein Families: ES Cell Differentiation/IPS, Transmembrane

Product images:



Immunohistochemistry staining of Paraffin Colon carcinoma tissue by Ep-CAM/Epithelial Specific Antigen antibody (dilution: 1:50 - 1:200; visualization of staining: Cytoplasmic)